

## SIRENOMELIA SYNDROME (CAUDAL DYSGENESIS): A CASE REPORT

Amrish Tiwari, DC Naik, PG Khanwalkar

Department of Anatomy, Shyam Shah Medical College, Rewa, Madhya Pradesh, India

Correspondence to: Amrish Tiwari (dramrishtiwari@gmail.com)

DOI: 10.5455/ijmsph.2014.020520141

Received Date: 16.04.2014

Accepted Date: 02.05.2014

**ABSTRACT**

Sirenomelia is a rare congenital anomaly with an incidence of one in 100,000 pregnancies. It is also called as Mermaid Syndrome because of fused leg, giving appearance of mermaid's tail. The cause of the condition is probably due to abnormalities in gastrulation in caudal segments. It was initially termed caudal regression, but it is clear that structures do not regress, they simply do not form. It is also known as caudal agenesis and sacral agenesis. Sirenomelia is characterized by varying degrees of flexion, inversion, lateral rotation, and fusion of the lower limbs. Other anomalies associated with this condition are, defects in lumbar and sacral vertebrae, renal agenesis, imperforate anus and agenesis of internal genital structures except the testes and ovaries. Its cause is unknown. It occurs sporadically but is most frequently observed among infants of diabetic mothers. This study points out a detail analysis of phenotypic features along with structural alteration of internal organs. The possible causes and outcome of the condition can be correlated, that may help in better understanding of the condition and provide clues for possible management.

**Key Words:** Sirenomelia Syndrome; Mermaid Syndrome; Caudal Regression; Sacral Agenesis

**Introduction**

The term "Sirenomelia" was derived from the Sirens of Greek and Roman mythology. The Sirens were three creatures with the head of a woman and the body of a bird from the wings down. They were dangerous to sailors, whom they narcotized with their enchanting music and voices to kill them later. However, despite the present perception of Sirens as romantic and cute creatures, in human it is a severe condition. It is a rare congenital anomaly with an incidence of one in 100,000 pregnancies.<sup>[1,2]</sup> Sirenomelia sequence, also known as Sirenomelia, Mermaid Syndrome, Caudal regression, Caudal agenesis and Sacral agenesis. It is a birth defect of the lower body characterized by the fusion of the legs into a single lower limb.<sup>[3]</sup> This striking external phenotype is associated with a variable combination of severe visceral abnormalities, most commonly urogenital and gastrointestinal, making Sirenomelia a multisystemic condition.<sup>[4,5]</sup>

In humans, the Currarino syndrome (a sacral agenesis caused by mutations in the homeobox-containing gene *HLXB9*) is associated with congenital caudal anomalies. In humans, Sirenomelia may be an autosomal dominant genetic condition and every single case is caused by a new spontaneous mutation. So the condition may be the result of combined genetic and environmental component. The familial cases, so far reported are two cases of diabetic mothers that had children with Sirenomelia and Caudal dysgenesis and

VACTERL association.<sup>[6-8]</sup>

The important environmental risk factors for caudal malformations are retinoic acid, maternal diabetes and heavy metals have been described. Exposure to heavy metals is associated with Caudal dysgenesis and Sirenomelia in both experimental models and in humans. Maternal diabetes is a causative environmental factor for Caudal dysgenesis in 10–15% of affected children. However, this association remains controversial for Sirenomelia because only 0.5%–3.7% of reported cases has diabetic mothers.<sup>[9-11]</sup>

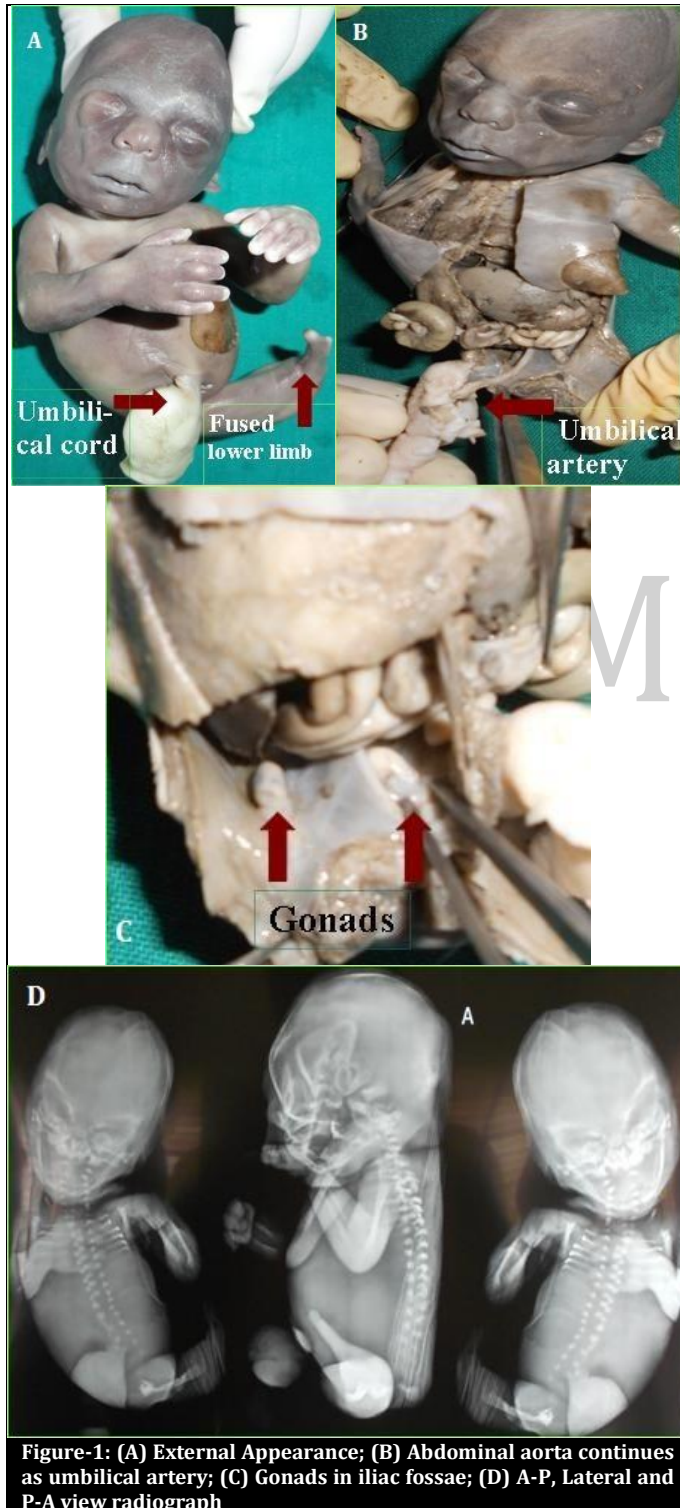
**Case Report**

A dead foetus of more than four months gestation brought from Department of Obstetrics and Gynaecology to Anatomy Department of Shyam Shah Medical College & Sanjay Gandhi Hospital, Rewa. External examination, radiological examination and dissection were done and findings were noted.

**External Examination:** Normal upper limbs, single lower limb, omphalocele, imperforate anus, external genitals absent, single umbilical artery in umbilical cord., rudimentary tail.

**Radiological Findings:** Single fused lower limb showing intermingled bones with slight gap in between them, no sacrum, and no pelvis. Vertebral column, ribs, skull bones and upper limb bones were normal.

**Dissection:** On dissection, we found a single umbilical artery that was the continuation of the abdominal aorta. Part of mid gut loop was outside the abdominal cavity in the covering of umbilical cord. Other findings were colonic atresia, absence of kidneys, ureters, and urinary bladder and lungs were hypoplastic. Gonads were normally present in iliac fossae (figure 1).



**Figure-1:** (A) External Appearance; (B) Abdominal aorta continues as umbilical artery; (C) Gonads in iliac fossae; (D) A-P, Lateral and P-A view radiograph

## Discussion

This birth defect occurs during 3rd week of gastrulation due to malformations in the intermediate mesoderm. There have been many theories about the etiology of the Mermaid syndrome.<sup>[12-14]</sup> Currently, there are two major theories described, according to Duhamel<sup>[15]</sup>, Sirenomelia was the most severe form of congenital anomalies. He postulated that a small localized lesion would lead to anal imperforation and mild vertebral anomalies, larger lesions would lead to urinary tract and gastrointestinal malformations and lastly, extreme lesions would cause lower limb fusion and anomalies associated with Sirenomelia. Secondly, Stevenson<sup>[16]</sup> described an alternate theory of vascular steal that has recently taken favor over caudal regression for the Mermaid syndrome. Stevenson et al. explained that in the Mermaid syndrome, blood is diverted from the caudal region of the embryo to the placenta producing a nutritional deprivation and abnormal development of the caudal structures.

Sirenomelia has been classified into three types according to the number of lower limb bones present:

- (i) Sirenomelia apus: No feet only one tibia and one femur.
- (ii) Sirenomelia unipus: One foot, two femurs two tibia, and two fibula.
- (iii) Sirenomelia dipus: Two feet and two fused legs giving the appearance of a flipper.

Sirenomelia dipus, also called as Mermaid syndrome, has the most favorable outcome. Survival of children with Sirenomelia depends on the associated visceral anomalies, especially renal function, rather than the Sirenomelia itself. Initial treatment of these newborns includes supportive care and diverting colostomy, later management of these infants includes a multidisciplinary surgical approach involving various specialties.<sup>[17]</sup>

## Conclusion

To conclude Sirenomelia is a rare fatal congenital malformation with severe visceral anomalies that decide the survival of foetus. Fusion of the lower limbs, which is very obvious, is less fatal. Few surviving patients need a multidisciplinary approach of treatment. In our case we found that the absence of urogenital organs and fused lower limbs may be due to deficient vascular supply, as umbilical artery was the continuation of abdominal aorta and distal to it aorta was absent.

## References

1. Källén B1, Castilla EE, Lancaster PA, Mutchinick O, Knudsen LB, Martínez-Frías ML, The cyclops and the mermaid: An epidemiological study of two types of rare malformation. *J Med Genet* 1992;29:30-5.
2. Assimakopoulos E, Athanasiadis A, Zafrakas M, Dragoumis K, Bontis J. Caudal regression syndrome and sirenomelia in only one twin in two diabetic pregnancies *Clin Exp Obstet Gynecol* 2004;31:151-3.
3. Stocker JT, Heifetz SA, Sirenomelia. A morphological study of 33 cases and review of the literature. *Perspect Pediatr Pathol* 1987;10:7-50. |
4. Stanton MP, Penington EC, Hutson JM. A surviving infant with sirenomelia (mermaid syndrome) associated with absent bladder. *J Pediatr Surg* 2003;38:1266-8.
5. Valenzano M, Paoletti R, Rossi A, Farinini D, Garlaschi G, Fulcheri E. Sirenomelia. Pathological features, antenatal ultrasonographic clues, and review of current embryogenic theories. *Hum Reprod Update* 1999;5:82-6.
6. Van Keirsblick J, Cannie M, Robrechts C, de Ravel T, Dymarkowski S, Va den Bosch T, et al. First trimester diagnosis of Sirenomelia. *Prenat Diagn* 2006;26:684-8.
7. Schiesser M, Holzgreve W, Lapaire O, Willi N, Luthi H, Lopez R, et al. Sirenomelia, the mermaid syndrome-detection in the first trimester. *Prenat Diagn* 2003;23:493-5.
8. Ladure H, D'herve D, Loget P, Poulain P. Prenatal diagnosis of Sirenomelia. *J Gynecol Obstet Biol Reprod (Paris)* 2006;35:181-5.
9. Zaw W, Stone DG. Caudal regression syndrome in twin pregnancy with type II diabetes. *J Perinatol* 2002;22:171-4.
10. Daveri tomha F, Googola M, Rovech M. Sirenomelia in an infant of a diabetic mother. *Acta Medica Iranica* 2003;41:69-72.
11. Assimakopoulos E, Athanasiadis A, Zafrakas M, Dragoumis K, Bontis J. Caudal regression syndrome and sirenomelia in only one twin in two diabetic pregnancies *Clin Exp Obstet Gynecol* 2004;31:151-3.
12. Valenzano M, Paoletti R, Rossi A, Farinini D, Garlaschi G, Fwcheri E, et al. Sirenomelia. Pathological features, antenatal ultrasound clues and a review of current embryogenic theories. *Hum Reprod Update* 1999;5:82-6.
13. Baxi L, Warren W, Collins MH, Timor-Tritsch IE. Early detection of caudal regression syndrome with transvaginal scanning. *Obstet Gynecol* 1990;75:486-90.
14. Duesterhoeft SM, Ernst LM, Siebert JR, Kapur RP. Five cases of caudal regression with an aberrant abdominal umbilical artery: further support for a caudal regression-sirenomelia spectrum. *Am J Med Genet A* 2007;143A:3175-84.
15. Duhamel B. From the mermaid to anal imperforation: the syndrome of caudal regression. *Arch Dis Child* 1961;36:153-5.
16. Stevenson RE, Jones KL, Phelan MC, Jones MC, Barr M Jr, Clericuzio C, et al. Vascular steal: the pathogenetic mechanism producing sirenomelia and associated defects of the viscera and soft tissues. *Pediatrics* 1986;78:451-7.
17. Messineo A, Innocenti M, Gelli R, Pancani S, Lo Piccolo R, Martin A. Multidisciplinary surgical approach to a surviving infant with sirenomelia. *Pediatrics* 2006;118:e220-3.

**Cite this article as:** Tiwari A, Naik DC, Khanwalkar PG. Sirenomelia syndrome (caudal dysgenesis): A case report. *Int J Med Sci Public Health* 2014;3:1022-1024.

**Source of Support:** Nil

**Conflict of interest:** None declared

IJMSPH